


**PATIENT**

Lulu Resendes

**PRESENTING CLINICAL SIGNS**

History: Murmur. Enlarged heart on radiographs.

**SPECIES**

Canine

**ECHOCARDIOGRAM FINDINGS**

2D, m-mode, color flow and doppler imaging is available. The mitral valve is diffusely thickened with prolapse into the left atrial lumen. There is severe eccentric mitral regurgitation present. The MR velocity is normal. There is severe left atrial enlargement. There is mild left ventricular dilation. Left ventricular systolic function is hyperdynamic. Mild right atrial and ventricular dilation (subjective). Thickening of the tricuspid valve with mild TR. Normal velocity. There is normal systolic flow velocity across the aortic valve. The aortic valve appears trileaflet with normal mobility. The main pulmonary artery is normal in diameter. The pulmonic valve is normal in appearance. No pericardial/pleural effusion or cardiac masses are seen.

**BREED**

Shih Tzu Mix

**SEX**

Female Spayed

**CARDIAC CHART**
**AGE**

12 years

CANINE CARDIAC PARAMETERS	MR VMAX (m/s)	TR VMAX (m/s)	LA/AO (Boon method)	LA/AO (Heart Base; Swe)	FS (%)	EF (%)	EPSS (cm)
NORMAL PARAMETER	4.5-5.5	<2.7	1.3	<1.6	28-40	40-100	<0.6
PATIENT	5.1	2.0	NM	2.0	50	83	NM
CANINE CARDIAC PARAMETERS	HR (BPM)	AV VMAX (m/s)	PV MAX (m/s)	BODY WEIGHT (kg)	LA 2D short axis Base view (cm)	LVIDd Avg: 2D and m-mode short axis (cm)	LVIDs Avg: 2D and m-mode short axis (cm)
NORMAL PARAMETER	50-100	0.7-1.7	0.7-1.6	BELOW	BELOW	BELOW	BELOW
PATIENT	175	1.1	0.8	3.8	2.4	3.1	1.3
*Normal chamber parameters expressed as a mean value (SD)				3	1.27 (5.3)	2.46 (2.46)	1.36 (5.5)
<b>BODY WEIGHT DEPENDENT PARAMETERS</b>				5	1.40 (4.5)	2.74 (5.2)	1.60 (4.7)
<i>*Note: All measurements based upon multi-modal images and methods. An average value is reported.</i>				10	1.50 (3.8)	3.27 (3.5)	2.06 (3.1)
				15	1.83 (2.0)	3.71 (2.4)	2.43 (2.1)
				20	2.02 (1.9)	4.14 (2.2)	2.80 (2.0)
				25	2.18 (2.4)	4.48 (2.9)	3.10 (2.5)
				30	2.33 (3.3)	4.83 (3.9)	3.39 (3.4)
				35	2.48 (4.3)	5.17 (5.0)	3.69 (4.5)
				40	2.62 (5.2)	5.48 (6.1)	3.96 (5.4)
				50	2.88 (7.1)	6.07 (8.3)	4.46 (7.4)

**INTERPRETATION OF THE FINDINGS & FURTHER RECOMMENDATIONS**

Chronic degenerative valve disease causing severe mitral and mild tricuspid regurgitation. The LA is significantly dilated indicating a high risk for clinical signs going forward. No additional concurrent issues such as systolic dysfunction are documented.

**INVOICE**

23440

With this degree of left heart changes, the risk for spontaneous congestive heart failure is elevated and cardiac supportive medications are indicated as below. A weak diuretic (spironolactone) is included given high risk for decompensation in the future even with no reported symptoms. Assessment of progression in the future will help predict long term outcome, however prognosis is guarded at this stage (late B2). Unfortunately, the patient

**DATE**

4/5/22

**INTERPRETED BY**

 Maggie Machen Lamy,  
 DVM DACVIM  
 (Cardiology)

**IMAGING PERFORMED BY**

Kelly Reschny, RVT

**HOSPITAL NAME**

 The Collegeway  
 Animal Hospital

**REFERRING VET**

Dr. Hanna



**PATIENT**

Lulu Resendes

will always be at risk for recurrent CHF, development of arrhythmias/LA tear, syncope and/or sudden death in the future.

**SPECIES**

Canine

Close monitoring for development of associated clinical signs (development of a cough, labored breathing, exercise intolerance or worsening collapse episodes) is recommended. Monitoring of sleeping breathing rates is recommended as the best way to screen for CHF at home.

**BREED**

Shih Tzu Mix

Elective anesthesia is not advised, as there is high risk for complication. If necessary, cardiac protective drug choices (opioid/benzodiazepine premedication, propofol or alfaxalone induction, iso or sevoflurane gas) are recommended. Pre-oxygenate for 5-10 minutes prior to induction and recover in O2 cage. Monitor for arrhythmias, hypotension, and hypoxia both intra and post-operatively and intervene as necessary. Moderate IV fluid restriction is recommended to avoid fluid overload. Avoid heart rate stimulating drugs such as atropine unless clinically indicated.

**SEX**

Female Spayed

**AGE**

12 years

Omega fatty acid supplementation and mild salt restriction may also be of some long-term benefit.

**WEIGHT**

8.4lbs

**PLAN**

A screening BP is recommended. Administer Pimobendan 0.3mg/kg PO q12h. Institute ACE-I (benazepril or enalapril) 0.5mg/kg PO q12h. Institute spironolactone 1-2mg/kg PO q12h.

**INTERPRETED BY**

Maggie Machen Lamy,  
DVM DACVIM  
(Cardiology)

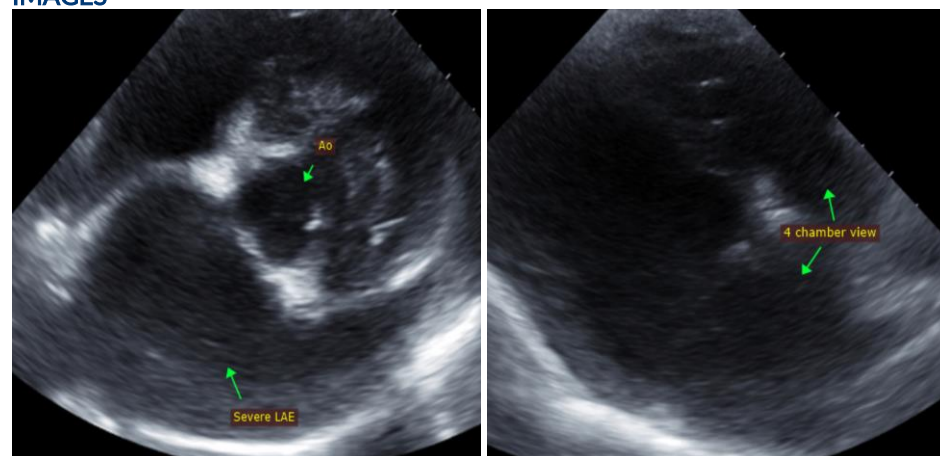
Monitor renal values in 1-2 weeks, then every 3-4 months lifelong to ensure tolerance of medications.

A recheck echocardiogram is recommended in 4-6 months to screen for progression, sooner if clinical signs arise.

**IMAGING PERFORMED BY**

Kelly Reschny, RVT

**IMAGES**



**HOSPITAL NAME**

The Collegeway  
Animal Hospital

**REFERRING VET**

Dr. Hanna

**INVOICE**

23440

**DATE**

4/5/22



**PATIENT**

Lulu Resendes

The information and recommendations provided are based on the images presented by the referring veterinarian. No evaluation can be communicated regarding pathology that was not visible in the image/video clips provided.

**SPECIES**

Canine

Thank you for this referral. This report was generated using transcription software, and minor dictation errors may be present. If the clinical or image interpretation does not parallel your findings or if I can be of any further assistance, please contact me.

**BREED**

Shih Tzu Mix

Maggie Machen Lamy, DVM  
Diplomate of the American College of Veterinary Internal Medicine (Cardiology)  
info@sonopath.com

**SEX**

Female Spayed

**AGE**

12 years

**WEIGHT**

8.4lbs

**INTERPRETED BY**

Maggie Machen Lamy,  
DVM DACVIM  
(Cardiology)

**IMAGING  
PERFORMED BY**

Kelly Reschny, RVT

**HOSPITAL NAME**

The Collegeway  
Animal Hospital

**REFERRING VET**

Dr. Hanna

**INVOICE**

23440

**DATE**

4/5/22